



Received: 6 March 2020
Accepted: 22 September 2020
Published: 1 July 2021

¹ Assistant Professor, Research
Institute for Cultural Heritage
and Tourism, Tehran, Iran,
(Corresponding Author).
E-mail: m.hadian@richt.ir

²Phd, Jam-e-Jam Imaging Center,
Tehran, Iran.

³ Phd in Archaeology, Zanzan
Cultural Heritage, Handicrafts
and Tourism Organization,
Zanzan, Iran.

⁴ Professor of Archaeology,
Research Laboratory for
Archaeology and the History of
Art, University of Oxford, UK
E-mail:
mark.pollard@arch.ox.ac.uk

How to cite this article:
Hadian Dehkordi, Manijeh, Jalal
Jalal Shokouhi, Abolfazl Aali,
Mark Pollard. (2021). Pathology,
Sex and Age Estimation to
Decode the 4th Salt Mummy, the
SaltMan in Zanzan, Iran, *The
International Journal of
Humanities* (2021) Vol. 28 (3):
(44-54).

<http://ejih.modares.ac.ir/article-27-40105-en.html>

RESEARCH ARTICLE

Pathology, Sex and Age Estimation to Decode the 4th Salt Mummy, the SaltMan in Zanzan, Iran

Manijeh Hadian Dehkordi¹ , Jalal Jalal Shokouhi², Abolfazl Aali³
Mark Pollard⁴

Abstract: Salt-man No.4 is the 4th natural mummy discovered in the archeological excavation in Chehr-Abad salt mine located in the western Iranian city of Zanzan in 2005. The mummy was a complete body, fully clothed and with leather boots, a silver earring and a few gadgets such as a metallic knife, ceramic pots and an oil lamp. Radiocarbon dating revealed that the mummy dates back to Achaemenid era 330-550 B.C. Total coverage and clothing as well as anatomy of the mummy including its forearm, delicate fingers and lack of beard and mustache raised some questions about its gender. In the light of the physical status of the mummy at its burial time, the other question was the cause of its death. It was necessary to get information about physical conditions and the severity of the damage incurred to the mummy in order to take conservation and preservation measures. X-Ray radiography and CT scan revealed the gender of the mummy as being a 15 to 16-year-old boy who had died as a result of crushing caused by the collapse of heavy stones at the mine that buried him underneath. The sudden death was caused by multiple bone fractures (trauma) and heart compression and rupture as a result of crushing falling stones.

Keywords: Mummy; Saltman; Zanzan; CT Scan; X-ray.

Introduction

In 1993, an accidental discovery of a mummy with a head, neck and a leg and long hair and beard dating back to some 1,700 years ago was announced. The discovery of this mummy took place at the Chehr-Abad salt mine located in Zanjan province in the western part of Iran. This mummy was dubbed the salt-man (Vatandoust and Hadian, 2005; Hadian, 1998).

Some ten years later, the second mummy was discovered in 2003. Consequently, more studious attention was paid to archeological excavations in the salt mine. In 2005, one of the most unique natural mummies was discovered in the eastern part of the workstation at the mine (Aali, 2006). Carbon age analysis by C14 at the University of Oxford revealed that the mummy dates back to the Achaemenid era (Baker, 2006).

The burial status of the mummy which was the fourth mummy discovered in the mine shows its position was face down under lots of salt stones and soil. As shown here (Fig. 1) the left lower limb was bent over the abdomen in the lower part and the left hand was used as

the support. All clothes of the 4th Salt-man including the long shirt and long pants were made of wool (Hadian, 2005; Yazdankhah Kenari, 2008). Not only clothes types but also delicacy of the forearm and fingers raised some questions about age and gender of the mummy.

Decoding the position of the mummy under soil and stones and having information about physical damage incurred upon it as well as the cause of its death were important not only from the archeological perspective but also for conservation purposes.

As non-invasive methods, radiological evaluation like X-Ray radiography and CT scan are important for archeological studies on human remains. The radiological examination of mummies began a few months after the discovery of X-ray by Roentegen in 1895 (Hoffman et al., 2002). Using this method, one could conduct pathological studies on various organs to diagnose illnesses and maladies during life, reasons and causes of death, and decay or damage sustained by natural mummies (Shin et al., 2014).



Fig. 1. Physical position of the 4th salt-man of Zanjan, Iran

Despite the positional and conditional limitation of X-ray examination on natural mummies (Bewes et al., 2016), we can use multiple modalities of radiology as a complementary method to glean the

maximum amount of information. For instance, limitations of plain radiography could be compensated with CT scan or computed diagonal tomography for different overlapping organs (Isherwood and Hart, 2006). Hence, to study these historic mummies, the non-invasive radiographic methods of X-ray and CT scan were used in the present study.

Methodology

Radiological studies on the 4th mummy of Zanjan were conducted by hospital portable 100 milliamperere and schimadzu 6800 CT scan with the gantry width of 70cm at the Jam-e-Jam Medical Imaging Center of Tehran in 2005 (Fig.2). The 3D reconstruction of skin and bone were made as SSD (surface shaded display).

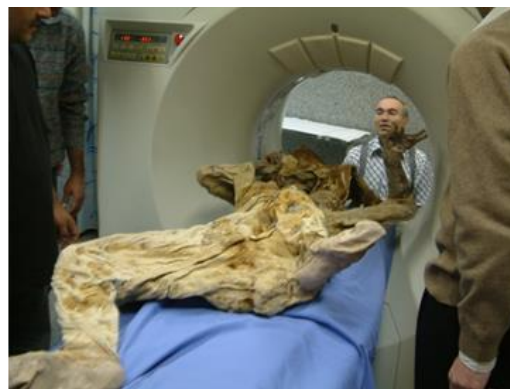

Fig. 2. CT scan of the 4th salt-man mummy at the Jam-e-Jam Medical Imaging Center

After the CT scan, we made a solid polymer specimen by SLA machine (Stereo Lithography) in Iran using CAD-CAM software. The physical model made of polymer was donated to Zanjan Museum. The 3D reconstruction model was made by 1mm scanning slice in real size scaling.

Results

X-ray Radiography

Due to the physical position of the mummy preventing placing of imaging cassettes between organs, only few possible plans were made. The X-ray radiography of the skull showed numerous fractures (Fig. 3). Orbital bones look normal but middle fracture of mandible (chin or mentom) and possible fractures in TMJ “temporomandibular joint” were seen.

Epiphyseal line in the proximal end of metacarpal long bone is not fused or open proving that it was a young man under the age of 22 (Greulich, 1990). Usually, bone age is estimated by X-ray of the left wrist (Greulich, 1990) but for this case we had to use the right wrist. Proximal epiphysis of 1st metacarpal

bone and also proximal epiphysis of 1st phalanx of thumb finger as well as the shape and size of the sesamoid bone showed that he was 15 or 16 years old (Fig. 4).

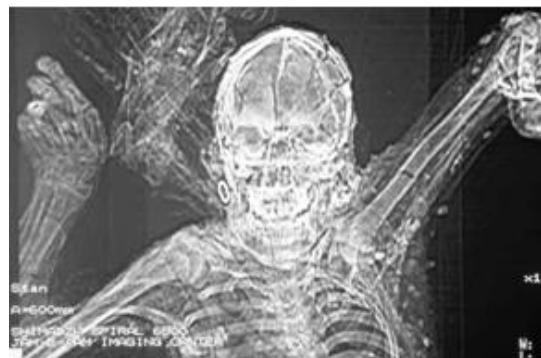

Fig. 3. X-ray of head, neck, thorax and hands of the 4th Salt-man with a silver ring on the right ear and a part of animal skin or something similar behind his head.

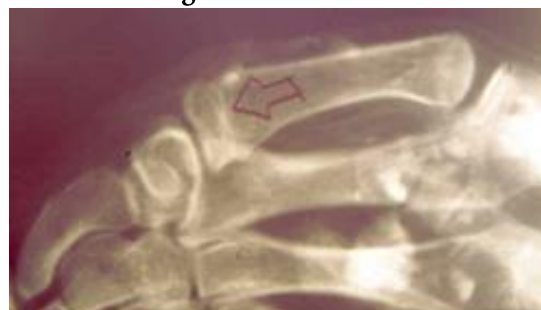

Fig. 4. Open proximal epiphysis of 1st phalynx of thumb finger and presence of sesamoid bone in the 4th salt-man

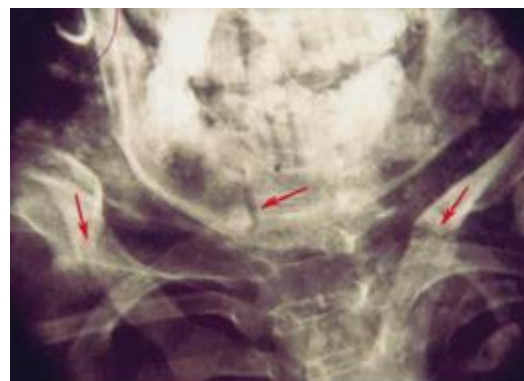

Fig. 5 X-ray or radiograph of clavicular and chin fractures

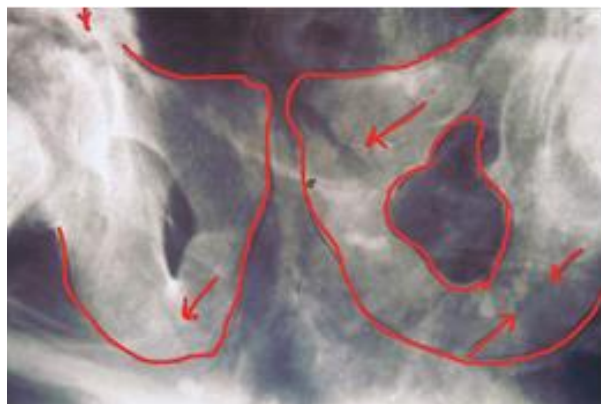

Fig. 6. Pelvis X-ray of the slat-man mummy which shows its gender to be male. The bone fractures could be seen in this section. This angle is about 60 degrees (proving it to be a male). In females it is about 110 degrees

Clavicular fractures on both sides were seen and the chin and the mentum were deviated to the right (Fig. 5).

Fracture of distal left radius and left humerus “arm” was seen on the mummy as well.

On the right side, the mid- part of humerus, condyles, distal part of the humerus, proximal and distal of radius and distal of ulna were fractured.

The non-fused epiphaseal line indicates the young age of the mummy.

Due to the flexing of the fingers on the left hand no detail examination was possible. For diagnostic and differentiation between

clothes, soft tissue and bone, we conducted three kinds of X-ray imaging namely low, adequate and high penetrated images.

The X-ray from the chest wall and lung shows left ribs 1-9 all fractured

The left knee was flexed into the abdomen and lower thorax was a limitation for imaging.

Suggestive fracture of bi-lateral clavicles was seen with possibilities of both scapular fractures.

X-ray images from abdomen and pelvis were taken from right side. The left knee converged on the left side of abdomen due to bending outside and upward.

On pelvis X-ray there is a fracture in the proximal end of the left femur. Left acetabulum is also fractured in multiple pieces. There are fractures in left iliac wing and sacrum. An interesting finding in the pelvis x-ray is the acute angle between iliac bones under pubic symphysis indicating male secularity of the 4th salt mummy (Fig. 6).

This angle is about 60 degrees in males and it is about 110 degrees in females (Fig. 7)

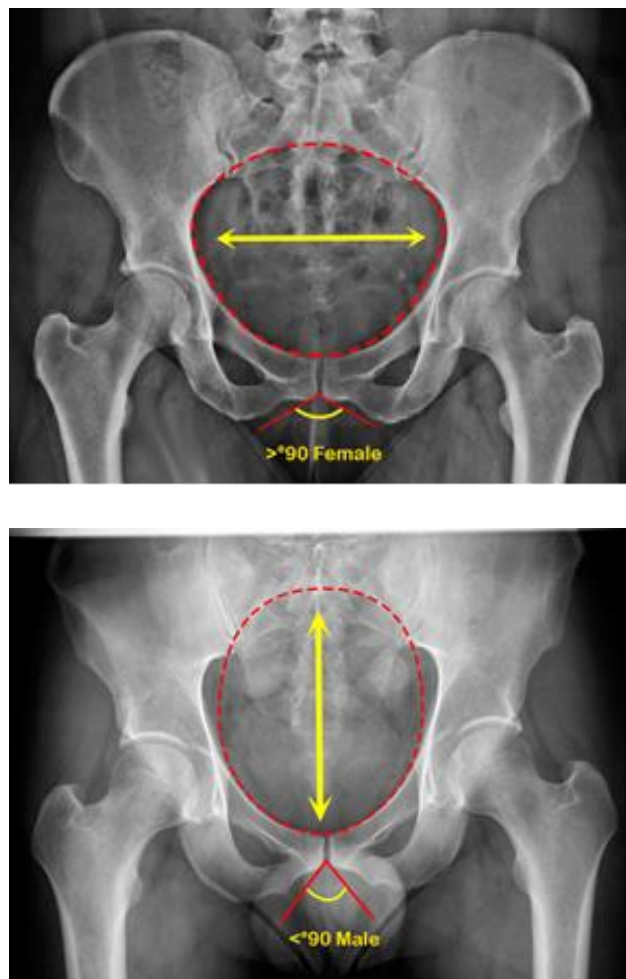


Fig. 7. Comparison between males and females in pelvis radiography
<https://radiopaedia.org/articles/pelvis-1>

In X-ray of lower limb, a cross sectional fracture of distal femur is seen. There are cross sectional fractures of tibia and fibula. All these fractures indicate a fulminant trauma on the 4th Salt-man. These images show multiple non-fused growth plate and open epiphysis. On the right foot in the boot no definite lesion is seen but because of boot shrinkage all toes

position are in flexion. This position is similar to 1st salt-man (Vatandoust and Hadian, 2005).

The Pelvis X-ray in the 4th Saltman (acute pubic angle) indicates male secularity and there is left pubic bone fracture.

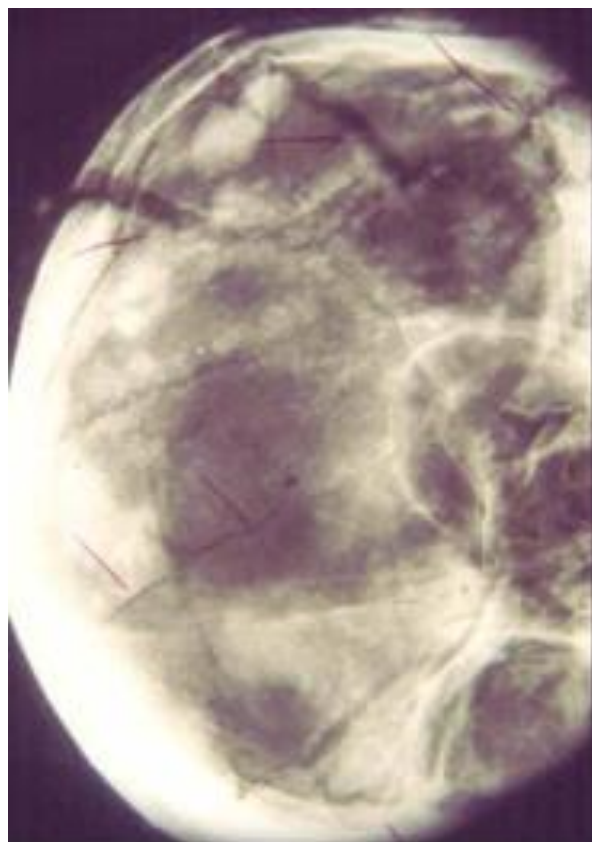


Fig. 8. Fractures on the skull of the 4th salt-man

3.2. CT Scan

On X-ray computed tomography “CT” multiple skull fractures and decreased AP diameter are seen due to severe and high pressure trauma and the positioning of head

between two solid and hard material “stone”. By this force all facial bones are broken and depressed. At left upper part of skull there is a bone defect like a small shallow basin (fig. 8). The brain tissue locates symmetrically in the interior part of the skull on frontal areas and this indicates prone and down positioned skull over years.

All facial skin shows folds and kinks due to underlying bone fractures.

Both temporal bones are fractured but bilateral internal auditory canals are intact. Both side labyrinths are normal. The orbital muscle is dried and saved. Both globs are disappeared or shrank. Ethmoidal cell and nasal cavities are intact.

Despite the questionable fracture line on mandible plain X-ray, CT scan showed no fracture in ramus, mandibular angles and temporo mandibular joints, but anterior midline fracture of mandible is confirmed.

By this fracture line other parts of mandible are saved from trauma. Nasal complex deviated to the right side. There is intact nasolacrimal canal.

OPG panoramic and 3D reconstruction of teeth showed 28 teeth, however four large teeth at the back both right and left are missing and the reason is not clear (Fig. 10).

By CT scan images, fractures on the right and left shoulders were seen. Chest images showed heart compression between sternum and dorsal spinal column, and they could be the cause of the immediate death of mummy (Fig. 11). In other words, the heart compression was the main fatal factor for the death of this young man whose deadly effect was more than head fractures and lung compression.

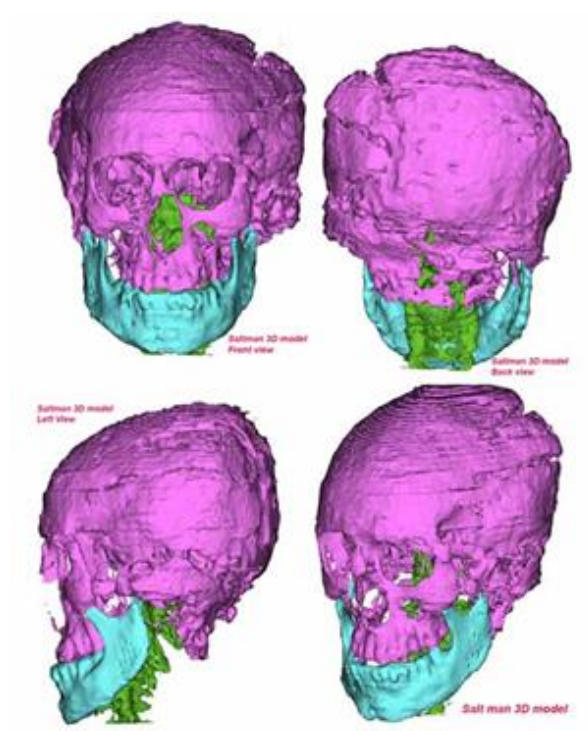


Fig. 9. 3D of 4th mummy's skull in multiple views

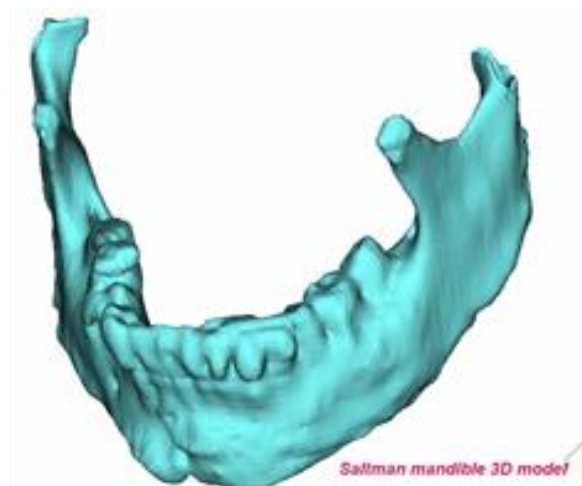


Fig. 10. 3D CT scan of 4th salt-man's mandible

The complex of both lungs are displaced and dried to anterior the chest and beside hilum of the lung (Fig. 11).

The left side of the chest was more compressed and the anterior of medial condyle of distal femur was located anterior to the abdomen and it is broken. Patella is normally located in its location.

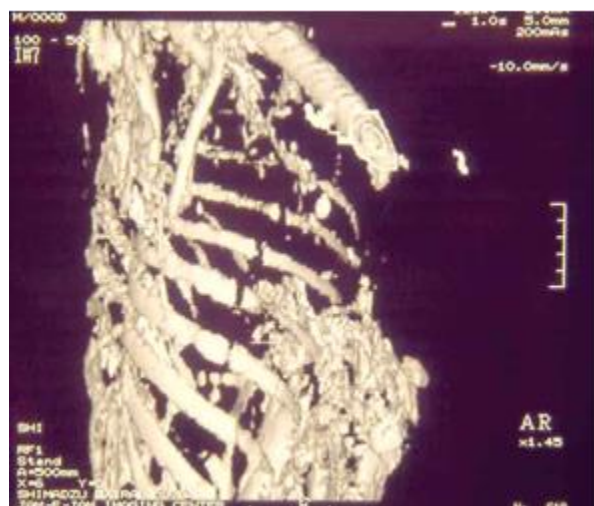


Fig. 11. 3D CT scan of chest cage

The 3D reconstruction of the leather boot images nicely showed all the structure and boot floor made in two layers where the outer layer is thick with higher density.

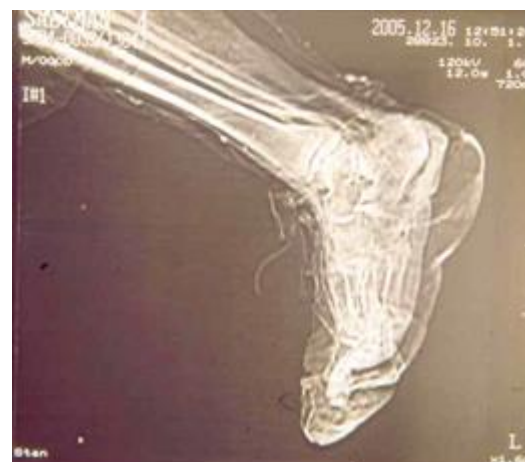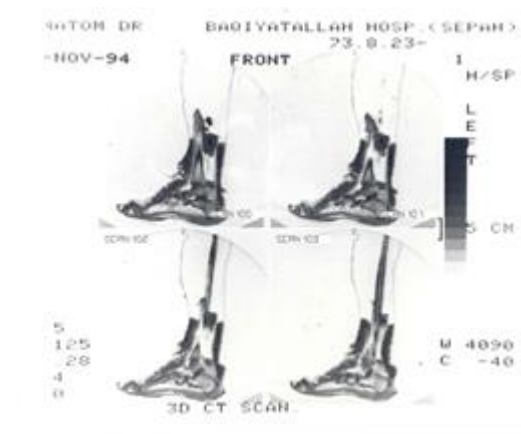


Fig. 12. 3D CT scan of the 4th mummy's foot and shoe (up) and CT scan of 1st mummy's foot and boot (down)

The solid prototype of the 4th salt-man was made using CAD-CAM technology and polymer. It has been dedicated to Zanjan museum (Fig. 13)

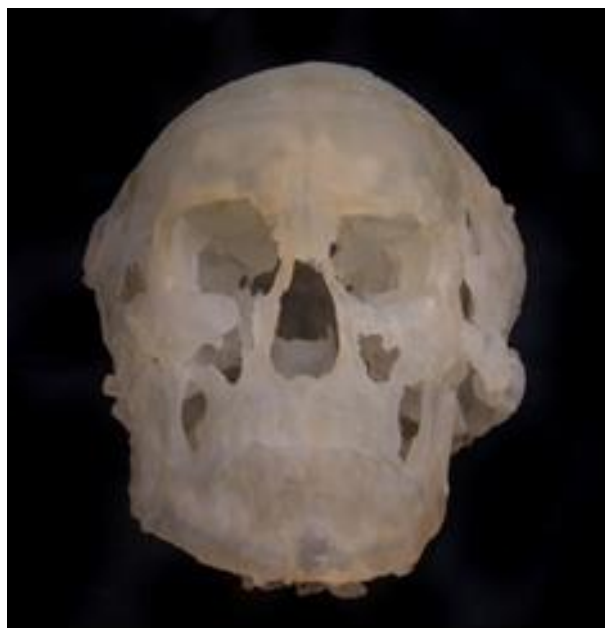

Fig. 13. Solid polymer model made by SLA machine (CAD/CAM)

Conclusion

Corresponding to the pubic angle in the pelvic X-ray, it can be asserted that the 4th mummy is male. 60 degrees in men and 110 degrees in women is an established fact.

The unfused epiphysis of the first phalanx of the thumb in both hands and the growth

plate of this phalanx indicates the age of the mummy to be 15-16 years old.

Multiple fractures across the body and especially cross-sectional fractures in long bones indicate that a heavy object has fallen on the victim and it has been the main cause of the immediate death in the form of heart compression or heart implosion. This trauma made by large salt stone at the mine. Location of the dried brain and lung parenchyma reveals the prone and head-down position of the corpse for so many years under the rubble.

Funding

This work was supported by the Research Institute for Cultural heritage and Tourism in Tehran.

References

- [1] Ali. A., (2005). 'Report on Saltmen'. Research Center for Archaeology, Tehran.
- [2] Baker, D., 2006. 'Report of the Radiocarbon Accelerator Dates on the Samples from Zanjan (Chehr-Abad)', Radiocarbon Accelerator Unit, Oxford University.
- [3] Greulich, W. W., Pyle, S. I., (1990). *Radiographic Atlas of Skeletal Development of the Hand and Wrist*, Second Edition, Stanford University Press.
- [4] Hoffman, H., Torres, E., Ernst, W. and Randy, D., (2002). 'Paleoradiology: Advanced CT in the Evaluation of Nine Egyptian Mummies', *RadioGraphics*, Volume 22, Issue 2.
- [5] Hadian Dehkordi, M., (1998). 'Salt Man. Scientific Investigations Carried out on Saltman Mummified Remains and its Artifacts'. Research Center for Conservation of Cultural Relics, Tehran.

-
- [6] Hadian Dehkordi, M., (2004). 'Report on Salt Man No. 4', Unpublished Manuscript, Research Center for Conservation of Cultural Relics, Tehran.
- [7] Isherwood, I., Hart, C. W., David, A.R and Tapp, E., (2006). The Radiological Investigation in: *The Mummy's Tale, the Scientific and Medical Investigation of Natsef Amun*, Priest in the Temple at Karnak, 100-112.
- [8] Bewes, M., Morphett, J., Antony, Pate, F. D., Henneberg, M., Low, J. A., Kruse, L., Craig, B., Hindson, A. and Adams, E., (2016). 'Imaging Ancient and Mummified Specimens: Dual-energy CT with Effective Atomic Number Imaging of Two Ancient Egyptian Cat Mummies', *Journal of Archaeological Science: Reports* 8, Pp. 173–177.
- [9] Doong Hoon, Sh., Chang Seok, O., Myeung Ju, K., Dong Soo, Y., In Sun, L., (2014). 'What could Radiological Study say about Korean Mummies? In: Pfeil , Friedrich, *Year Book of Mummy Studies*, München, Germany, Vol. 2, pp. 125-131.
- [10] Shokouhi, J.J. (2005). 'Radiographic Report on Saltman No.4'. Unpublished Manuscript, Jam-e-Jam , Tehran.
- [11] Pollard , A. M., Brothwell, D.R., Aali, A., Buckley, S., Fazeli, H., Hadian Dehkordi, M., Holden, T., Jones, A.K.G., Shokouhi, J.J., Vatandoust , R., Wilson, A.S. (2008). Below the Salt: a Preliminary Study of the Dating and Biology of Five Salt-preserved Bodies from Zanjan province, *Iran*, Vol. 46, Pp. 135-150.
- [12] Vatandoust, R; Hadian Dehkordi, M., (2005). 'Saltman, a New Archaeological Discovery: Scientific Investigation and Conservation', *Journal of Biological Research*, Pp. 236-242.
- [13] Yazdankhah Konari, F., (2008). 'Conservation and Restoration of Textiles Discovered in Zanjan Saltmine (Thesis), Tehran Art University.




تاریخ دریافت: ۱۳۹۸/۱۲/۱۶

تاریخ پذیرش: ۱۳۹۹/۷/۱

تاریخ انتشار: ۱۴۰۰/۴/۱۰

مطالعات آسیب‌شناسی و تعیین سن و جنسیت برای رمزگشایی از چهارمین مومیایی نمکی مکشوفه از معدن نمک زنجان

منیژه هادیان دهکردی^۱ , جلال جلال شکوهی^۲، ابوالفضل عالی^۳، مارک پولارد^۴

چکیده: مومیایی شماره ۴، چهارمین مومیایی طبیعی مکشوفه از معدن نمک چهلآباد زنجان در غرب ایران است که در سال ۱۳۸۳ در کاوش باستان‌شناختی کشف شد. این مومیایی پیکره کامل جسدی با پوشش کامل شامل لباس، کفش چرمین با یک گوشواره نقره و برخی ابزار همچون چاقوی آهنی، ظرف سفالی به احتمال پیه‌سوز بوده است. نتایج سالیابی کربن ۱۴ که در دانشگاه آکسفورد صورت گرفت، نشان داد که این مومیایی متعلق به دوره هخامنشی (۵۵۰-۳۳۰ پیش از میلاد) است. پوشش کامل و شکل ظاهری آن (ساعد و انگشتان ظریف و صورت بدون مو) منجر به طرح پرسش درباره جنسیت و سن مومیایی شد. علاوه بر این با توجه به وضعیت فیزیکی مومیایی در زمان دفن، علت مرگ آن در زمان حیات یکی دیگر از پرسش‌های مطرح درباره این مومیایی بود. از سوی دیگر به منظور اقدامات حفاظتی و نگهداری این اثر نیازمند آگاهی از شرایط فیزیکی و شدت آسیب‌های وارد بر آن بود. نتایج سی‌تی اسکن و رادیوگرافی اشعه ایکس قابل حمل نشان می‌دهد که این مومیایی جسد پسر نوجوان ۱۶-۱۵ ساله است که در اثر سانحه ریزش معدن نمک در محل مدفون شده بود. ضربه شدید و برق‌آسای وارد بر آن علاوه بر شکستگی‌های زیاد در سراسر بدن این مومیایی به علت فشردگی شدید قلب باعث مرگ آنی آن شده بوده است.

واژه‌های کلیدی: مومیایی، مرد نمکی، زنجان، سی‌تی اسکن، پرتو ایکس.

^۱استادیار پژوهشکده حفاظت و مرمت آثار تاریخی-فرهنگی، پژوهشگاه میراث فرهنگی و گردشگری، تهران، ایران (نویسنده مسئول).

E-mail:
m.hadian@richt.ir

^۲دکتری رادیولوژی و رئیس انجمن رادیولوژی ایران، تهران، ایران

^۳دکتری باستان‌شناسی، اداره کل میراث فرهنگی، گردشگری و صنایع دستی استان زنجان، ایران.

^۴استاد علوم باستان‌شناختی، دانشگاه آکسفورد، بریتانیا.